

Long-term Results of Corneal Wedge Resection for High Postkeratoplasty Astigmatism

Luis F. Mejía, MD,* Juan C. Gil, MD,† and Santiago Naranjo, MD†

Purpose: To present the results of corneal wedge resection in postkeratoplasty astigmatism, performed by the same surgeon using the same nomogram over a 25-year period.

Methods: This is a retrospective observational study. The sample was obtained from the medical records of all patients who underwent penetrating or deep lamellar keratoplasty, performed by a single surgeon from 1993 to 2018. All surgeries were performed using a diamond knife, on the flat meridian, involving the keratoplasty scar and closed with five 10-0 nylon sutures.

Results: A total of 39 eyes were included. The keratometry measured cylinder improved from 7.99 ± 0.25 to 2.5 ± 0.3 D at 12 months and remained stable thereafter (a mean follow-up of 76.3 months). Best spectacle corrected visual acuity increased from 0.35 ± 0.01 to 0.57 ± 0.02 at 12 months and remained stable thereafter. There was a coupling ratio of 0.08 ± 0.03 D at 12 months. There were no corneal graft rejections or loss of best spectacle corrected visual acuity on this series.

Conclusions: Corneal wedge resection is a valuable resource for the management of high postkeratoplasty astigmatism. It is a safe and reproducible procedure, with stable results at 12 months and thereafter.

Key Words: crescent resection, astigmatism, keratoplasty

(*Cornea* 2020;39:535–539)

A corneal graft is the most frequently performed homologous human transplant worldwide¹ and has been performed on a regular basis for the past 50 years. Its results are increasingly better because of a better understanding of the eye's anterior segment physiology and improved surgical materials and techniques.^{2–4}

However, postoperative astigmatism is a persistent problem,⁵ making patient rehabilitation a challenge, and sometimes even nullifying the surgical result.

In an effort to attenuate its magnitude, different trephination techniques and donor/recipient disparities^{6,7} as well as different suturing techniques^{8,9} have been tried, but they are still far from being reasonably predictable; in some cases, the astigmatism is of great magnitude [up to 12 Diopters (D)],^{10–12} placing at risk the functional viability of the graft itself.

The corneal wedge resection procedure was first published by Troutman in 1997,¹³ in an effort to deal more effectively with this problem. It has shown reasonably good results, but the series published are small, employing different nomograms, surgical techniques, and follow-up periods; this heterogeneity has discouraged many corneal surgeons from embracing it.

In this paper, we present our 25-year experience performing corneal crescent resection in cases of postkeratoplasty (penetrating—PK or deep lamellar—DALK) astigmatism equal to or greater than 6 D, performed by the same surgeon (L.F.M.), using the same nomogram and surgical technique.

MATERIALS AND METHODS

Data Collection and Study Design

A retrospective observational study was planned and approved by the Ethics Committee of Universidad CES. Medical records from patients who underwent surgery performed by one surgeon (L.F.M.) were reviewed, identifying all those who had undergone a corneal crescent resection to correct postkeratoplasty (PK or DALK) astigmatism of 6 D or greater, between 1993 and 2018 with a minimum follow-up period of 12 months.

Variables included age at surgery, type of keratoplasty, indication for keratoplasty, K1 and K2 readings, axis, uncorrected visual acuity, and best spectacle corrected visual acuity (BSCVA). Preoperative data, and postoperative data at 3, 6, and 12 months, and the last registered visit were obtained.

Surgical Technique

All original keratoplasties and wedge resections were performed by the same surgeon. On the initial keratoplasty surgery, a Hessburg-Barron trephine was used in both the donor and the recipient. In the DALK cases, the big bubble

Received for publication July 23, 2019; revision received August 21, 2019; accepted September 3, 2019. Published online ahead of print November 4, 2019.

From the *Cornea Service, School of Medicine, CES University, Medellín, Colombia; and †Ophthalmology Research Service, School of Medicine, CES University, Medellín, Colombia.

The authors have no funding or conflicts of interest to disclose.

Supplemental digital content is available for this article. Direct URL citations appear in the printed text and are provided in the HTML and PDF versions of this article on the journal's Web site (www.corneajrnl.com).

Correspondence: Luis F. Mejía, MD, Cra 25A #1-31, Ofic 914, Medellín, Colombia (e-mail: lfmejia@lfmejia.com).

Copyright © 2019 Wolters Kluwer Health, Inc. All rights reserved.

technique was employed, and in the event of even a small perforation, surgery was converted to PK. In PK grafts, the donor diameter was 0.25 mm larger than the recipient bed, except in keratoconus cases, where it was the same; in DALK cases, it was always the same.

All grafts were sutured with 12 10-0 nylon sutures, which began to be selectively removed at 4 months in the DALK patients and at 12 months in the PK patients so that at 24 months post-op all sutures had been removed. We waited 6 months after the last suture was removed for astigmatism to stabilize and then proceeded to its correction, according to its magnitude.

In all patients, the surgical nomogram employed was a 90-degree arc wedge resection on the host side, removing 0.1 mm per diopter of subjective astigmatism up to 6 D and from there on removing 0.05 mm per each additional diopter (nomogram source: Francisco Barraquer, MD. Clínica Barraquer, Bogotá, Colombia). Therefore, for a 6-D astigmatism, the maximum wedge width was 0.6 mm, whereas for a 13-D astigmatism, it was 0.95 mm. The resection was made on the flattest meridian, and the hemimeridian was chosen according to the flattest one on the corneal topography. The resection axis was marked pre-op at the slit lamp, and at surgery, the resection was demarcated 45 degrees to each side of it; the maximum width of the crescent to be resected was marked with a personal caliper, pertaining to the surgeon, exactly on the axis demarcated preoperatively, and using a single-bladed diamond knife set at 100% pachymetry, an incision was made until reaching 90 degrees of arc, first on the host and then directly on the keratoplasty scar, keeping resection borders vertical (not wedge shaped), to the pre-Descemet's level; once dissected, the crescent end was grasped with toothed forceps and its floor sectioned with Vannas scissors; a paracentesis was made 90 degrees away and the wound was closed with 5 interrupted 10-0 nylon sutures burying knots in the host, aiming at inducing a 100% hypercorrection (see Video, Supplemental Digital Content 1, <http://links.lww.com/ICO/A916>). After surgery, a combination of antibiotic and steroid eye drops was indicated 5 times a day for 1 month.

Patients were followed up the next day, at 1 week, at 1, 2, 3, 6, and 12 months after surgery, and yearly thereafter, and sutures began to be removed at the second post-op month according to the present astigmatism.

Data Analysis

For the variable analysis, SPSSA software version 21.0 for iOS was used. The presentation for quantitative variables was showed according to their distribution, and it was calculated with the Shapiro–Wilk normality test. A student *t* test for independent and paired data was performed, and a 0.05 Alpha was used. All categorical variables were displayed as frequency and percentage.

RESULTS

A total of 39 eyes were included, of which 22 (56.4%) belonged to men and 17 (43.6%) to women. The main surgical indications for keratoplasty were keratoconus

(38.5%), bullous keratopathy (17.9%), trauma (15.4%), mycotic keratitis sequelae (10.3%), bacterial keratitis sequelae, HSV sequelae and post-LASIK ectasia (5.1% each), and acanthamoeba keratitis sequelae (2.6%). There were 26 PK (66.7%) and 13 DALK (33.3%) eyes. The mean post-operative follow-up was 76 months (range 14–160 months); 14 patients had a follow-up longer than 10 years. The main results of the study are shown in Table 1.

The total keratometric cylinder decrease compared with the pre-op data was 5.9 ± 0.3 , 5.3 ± 0.3 , and 5.2 ± 0.3 D at 3, 6, and 12 months follow-up respectively, remaining stable thereafter to the last follow-up, where it was 5.15 ± 0.3 D.

The decrease in keratometric cylinder (D) compared with the pre-op value for PK and DALK was very similar and nonsignificant between the 2 types of keratoplasties (Table 2).

Astigmatism Variation

At the first month post-op (data not shown), most patients had an important—and expected—hypercorrection of the initial astigmatism, which partially and gradually receded at the end of the second month, where selective suture removal was initiated.

The initial keratometric astigmatism was 7.9 ± 0.2 , and 2.4 ± 0.3 D at the last visit (average 76 months). Progression of keratometric astigmatism is shown in Table 1 and Figure 1. K1 readings improved significantly at all intervals compared with pre-op measurements, whereas K2 reading variation was negligible. The coupling effect (0.08 ± 0.03) was nonstatistically significant.

Pre-op refractive astigmatism was 6.54 D, corrected to 2.24 D at 12 months post-op, without any statistically significant variation from there on, being 2.30 D at the last follow-up (mean 76.3 months).

In 2 eyes (5.1%), there was no effective modification of their keratometric astigmatism, with a reduction of just 0.25 and 0.5 D: both were men, aged 19 and 26, with a pre-op diagnosis of keratoconus; one underwent PK and the other DALK.

Visual Acuity

Uncorrected visual acuity (UVA) varied as follows: 0.04 pre-op, 0.13 at 3 months, 0.14 at 6 months, 0.16 at 12 months, and 0.16 at the last visit ($P < 0.05$ for all intervals compared with the pre-op value).

BSCVA varied as follows: 0.35 pre-op, 0.42 at 3 months, 0.49 at 6 months, 0.57 at 12 months, and 0.58 at the last visit ($P < 0.05$ for all intervals compared with the pre-op value). No patient lost any lines of BSCVA after surgery (Fig. 1).

Complications

In 2 eyes, there was a microperforation at the base of the corneal resection during the diamond knife keratotomy, without anterior chamber depth variation, which was repaired with the subsequent suturing of the surgical wound. In 2 patients, a suture was loose before the second post-op week,

TABLE 1. Main Results of the Study

Variable	Mean ± SD		P*	Mean ± SD		P*	Mean ± SD		P*
	Pre	3 m		6 m	12 m		Last Visit		
K1	37.6 ± 0.4	43.5 ± 0.4	<0.05	42.9 ± 0.4	<0.05	42.8 ± 0.4	<0.05	42.7 ± 0.4	<0.05
K2	45.6 ± 0.4	45.4 ± 0.4	0.09	45.4 ± 0.4	0.09	45.3 ± 0.4	0.07	45.1 ± 0.3	0.07
Keratometric cylinder	7.9 ± 0.2	1.9 ± 0.3	<0.05	2.5 ± 0.3	<0.05	2.45 ± 0.3	<0.05	2.3 ± 0.3	<0.05
Spherical equivalent	-4.1 ± 0.4	-1.9 ± 0.4	<0.05	-1.9 ± 0.4	<0.05	-1.9 ± 0.3	<0.05	-1.9 ± 0.3	<0.05
UCVA	0.04 ± 0.005	0.13 ± 0.017	<0.05	0.14 ± 0.014	<0.05	0.16 ± 0.018	<0.05	0.16 ± 0.018	<0.05
BSCVA	0.35 ± 0.01	0.42 ± 0.017	<0.05	0.49 ± 0.018	<0.05	0.57 ± 0.025	<0.05	0.580 ± 0.02	<0.05

Student *t* for dependent variables.

*Comparison with preoperative values.

Mean SD, mean ± standard deviation; K1, steepest corneal meridian; K2, flatter corneal meridian; and UCVA, uncorrected visual acuity.

and it was replaced under topical anesthesia without complications. There were no cases of graft rejection in any patient following surgery up to the last control.

DISCUSSION

Corneal grafting is one of the most successful transplants in medicine. In 2018 alone, more than 45,000 corneal grafts were done in the United States of America.¹⁴

During recent decades, cornea surgeons have been able to perfect corneal grafting, thereby transplanting the diseased cornea layer selectively: full thickness, deep lamellar, or endothelial, according to the patient’s underlying pathology.¹⁵ This has brought enormous benefits to patients such as a reduction of graft rejections from 21% in PKs¹⁶ to 8% in DSAEK¹⁷ and 1% in DMEK¹⁸; a decreased risk of expulsive hemorrhage during surgery and traumatic rupture during the early or late post-op periods in deep lamellar and endothelial grafts, a decrease in suture related problems, and a significant reduction in the incidence of glaucoma.¹⁹

However, there is an unresolved issue with PK and DALK grafts which is the unpredictable incidence and magnitude of postoperative astigmatism. All cornea surgeons have post-op astigmatism after PK or DALK grafts; most of these are easily manageable though: glasses up to 3 D, relaxing keratotomies on the steeper meridian up to 5 to 6 D²⁰ (having the disadvantage of being paired and having a strong coupling effect which increases myopia already present in most of keratoconus patients), PRK²¹ (whose haze risk increases with increasing refractive corrections), and LASIK²² (with the regression and instability issue induced by the graft–host keratoplasty interface). All cornea surgeons use these options but

up to 15% to 20% of corneal grafts have an astigmatism greater than 5 D; some of them up to 10 to 20 D^{7,12}; in these patients—with astigmatism over 6 D—management is more complex and options are fewer.

A plausible option for these cases is a corneal crescent resection, a procedure first published by Troutman,¹³ its foundations set by Barraquer²³ years earlier; this procedure is performed on the flattest meridian.

Troutman proposed a 0.1-mm corneal crescent-shaped resection per diopter of astigmatism on a 90-degree arc. Several variations on this technique have been published since. Some perform the resection at the limbus,^{24,25} some exclusively on the host cornea, some straddling the keratoplasty scar,¹⁰ others exclusively on the graft side,^{26,27} and some coupled with relaxing keratotomies.¹⁰ There are multiple nomograms too: the most frequently used is the one originally published by Troutman¹³; other authors use Troutman’s nomogram reduced by 16% to 18% to avoid hypercorrections²⁶; and others just resect the scar tissue at the donor–recipient interface dismissing the astigmatism magnitude.¹⁰ Some authors have used metallic knives^{24,28,29} for the resection, others diamond knives,¹⁰ and some the femtosecond laser,³⁰ aiming at incision depths between 80% and 100%^{24,28,31} and using variable arc lengths.^{24,28}

Hence, published results are variable, with series size, follow-ups, and achieved corrections very dissimilar.^{24,26–28,32,33} However, they have in common achieving reasonable results,

TABLE 2. Keratometric Change, PK Versus DALK

	PK	DALK	P*
Change in mean K at 3 mo	5.9 ± 0.3	6.2 ± 0.6	0.47
Change in mean K at 6 mo	5.4 ± 0.3	5.8 ± 0.6	0.39
Change in mean K at 12 mo	5.4 ± 0.3	5.8 ± 0.6	0.35
Change in mean K at the last visit	5.4 ± 0.3	5.9 ± 0.6	0.1

*Student *t* for independent variables.

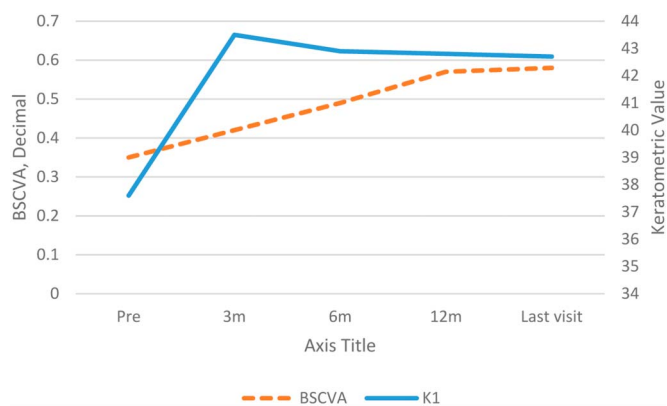


FIGURE 1. BSCVA and K1 change over time.

working on the flat axis, and sometimes having unexplained hypercorrections or hypocorrections.

To our knowledge, this is the largest series of patients operated on and followed up by one surgeon. We performed a 90-degree parallel-sided crescent-shaped corneal resection, on the host side, involving the keratoplasty scar because it is there where most of this post-op astigmatism originates.

We obtained a significant and stable reduction of the keratometric and refractive astigmatism from a mean pre-op of 7.99 and 6.54 D, respectively, to 2.45 and 2.24 D at 12 months post-op, without any statistically significant variation from there on, being 2.33 and 2.30 D at the last follow-up (mean 76.3 months). BSCVA improved from 0.35 pre-op to 0.57 at 12 months without a statistically significant variation from there on, being 0.58 at the last follow-up; this, probably not only due to the reduction of the astigmatism per se but also due to regularization of the corneal surface by doing surgery on the flatter hemimeridian. It is to be noted that we did not remove all sutures on all patients; in some patients we did, when deemed necessary, to achieve the refractive goal at 6 months post-op. But when it was not necessary to remove the sutures, we left them in place, removing them only if they were loosened or broken. However, we would like to point out that with the passage of years, when we had to remove loosened or broken sutures, there was no refractive consequence of doing so and patients did not lose refractive correction after doing so.

We would like to highlight that different from most published series,^{24,26,30} we did not find a significant coupling effect on the statistical analysis (0.08 ± 0.03), which is clinically evident by the lack of increase in the myopic spherical equivalent.

As far as we know, we are the first group to compare the results of the wedge resection in PK versus DALK patients. Not surprisingly, we did not find any difference in the results between both groups, as we always perform our crescent resection at the pre-Descemet level.

We—as other surgeons who use this same procedure^{24,28}—occasionally have a patient whose astigmatism does not change. In this series, we had 2 such patients (5.1%); both were men, aged 19 and 26 years, with a keratoconus. One underwent PK and the other one DALK. We reviewed their clinical records extensively and did not find an explanation for the lack of effect of the crescent resection.

We did not have any serious complications in our series and—specifically—had no case of graft rejection or graft failure. Operating on the host side probably diminishes the endothelial cell count loss on the donor.

We are aware that this technique has several flaws, including the caliper measurement itself, the fact that the wedge delineation is performed free-handedly and that suture tightness is highly subjective.

We have been performing corneal crescent resection for over 25 years and found the results to be satisfactory and stable over time. Our surgery is based on only one nomogram, inducing a marked hypercorrection in the early post-op, being aware that at 12 months our patients will have much lesser astigmatism, more regular corneas, and a better BSCVA.

Corneal crescent resection surgery is a safe and reasonably predictable procedure, worthy to be considered

in those cases of high postkeratoplasty astigmatism, where other surgical techniques are insufficient.

REFERENCES

- Gain P, Jullienne R, He Z, et al. Global survey of corneal transplantation and eye banking. *JAMA Ophthalmol.* 2016;134:167–173.
- Choi JA, Lee MA, Kim MS. Long-term outcomes of penetrating keratoplasty in keratoconus: analysis of the factors associated with final visual acuities. *Int J Ophthalmol.* 2014;7:517–521.
- Arora R, Jain P, Jain P, et al. Results of deep anterior lamellar keratoplasty for advanced keratoconus in children less than 18 years. *Am J Ophthalmol.* 2016;162:191–198.
- Chaurasia S, Price FW, Gunderson L, et al. Descemet's membrane endothelial keratoplasty: clinical results of single versus triple procedures (combined with cataract surgery). *Ophthalmology.* 2014;121:454–458.
- Riddle HK, Parker DAS, Price FW. Management of postkeratoplasty astigmatism. *Curr Opin Ophthalmol.* 1998;9:15–28.
- Feizi S, Zare M. Current approaches for management of postpenetrating keratoplasty astigmatism. *J Ophthalmol.* 2011;2011:1–8.
- Williams K, Keane M, Galetti R, et al. *The Australian Corneal Graft Registry 2015 Report*; 2015:1–409. Available at: <https://dspace.flinders.edu.au/xmlui/handle/2328/35402>. Accessed June 12, 2019.
- Van Meter WS, Gussler JR, Solomon KD, et al. Postkeratoplasty astigmatism control: single continuous suture adjustment versus selective interrupted suture removal. *Ophthalmology.* 1991;98:177–183.
- Shumway CL, Aggarwal S, Farid M, et al. Penetrating keratoplasty using the Femtosecond laser: a comparison of postoperative visual acuity and astigmatism by suture pattern. *Cornea.* 2018;37:1490–1496.
- Belmont SC, Lazzaro DR, Muller JW, et al. Combined wedge resection and relaxing incisions for astigmatism after penetrating keratoplasty. *J Refract Surg.* 1995;11:472–476.
- Williams KA, Roder D, Esterman A, et al. Factors predictive of corneal graft survival: report from the Australian corneal graft registry. *Ophthalmology.* 1992;99:403–414.
- Olson RJ, Pingree M, Ridges R, et al. Penetrating keratoplasty for keratoconus: a long-term review of results and complications. *J Cataract Refract Surg.* 2000;26:987–991.
- Troutman RC. *Microsurgery of the Anterior Segment of the Eye*. St. Louis, MO: Mosby; 1997:263–286.
- Eye Bank Association of America [Internet]. 2018. Available at: <https://restoresight.org/what-we-do/publications/statistical-report/>. Accessed July 15, 2019.
- Röck T, Landenberger J, Bramkamp M, et al. The evolution of corneal transplantation. *Ann Transpl.* 2017;22:749–754.
- Ing JJ, Ing HH, Nelson LR, et al. Ten-year postoperative results of penetrating keratoplasty. *Ophthalmology.* 1998;105:1855–1865.
- Wu EI, Ritterband DC, Yu G, et al. Graft rejection following descemet stripping automated endothelial keratoplasty: features, risk factors, and outcomes. *Am J Ophthalmol.* 2012;153:949–958.
- Price FW, Feng MT, Price MO. Evolution of endothelial keratoplasty. *Cornea.* 2015;34:S41–S47.
- Baltaziak M, Chew HF, Podbielski DW, et al. Glaucoma after corneal replacement. *Surv Ophthalmol.* 2018;63:135–148.
- Ho Wang Yin G, Hoffart L. Post-keratoplasty astigmatism management by relaxing incisions: a systematic review. *Eye Vis.* 2017;4:1–7.
- Kuryan J, Channa P. Refractive surgery after corneal transplant. *Curr Opin Ophthalmol.* 2010;21:259–264.
- Vajpayee RB, Sharma N, Sinha R, et al. Laser in-situ keratomileusis after penetrating keratoplasty. *Surv Ophthalmol.* 2003;48:503–514.
- Barraquer JI. Basis of refractive keratoplasty-1967. *J Refract Surg.* 1989; 5:179–193.
- Geggel HS. Limbal wedge resection at the time of intraocular lens surgery for reducing postkeratoplasty astigmatism. *Ophthalmic Surg.* 1990;21:102–108.
- Jensen RP, Jensen AC. Surgical correction of astigmatism by micro-wedge resection of the limbus. *Ophthalmology.* 1978;85:1288–1298.
- Frucht-Pery J. Wedge resection for postkeratoplasty astigmatism. *Ophthalmic Surg.* 1993;24:516–518.
- Ezra DG, Hay-Smith G, Mearza A, et al. Corneal wedge excision in the treatment of high astigmatism after penetrating keratoplasty. *Cornea.* 2007;26:819–825.

28. Hoppenreijns VPT, Van Rij G, Beekhuis WH, et al. Long-term results of corneal wedge resections for the correction of high astigmatism. *Doc Ophthalmol.* 1990;75:263–273.
29. van Rij G, Vijfvinkel G. Correction of postkeratoplasty astigmatism by razor blade and V-shaped knife wedge resection. *Ophthalmic Surg.* 1983; 14:406–410.
30. Ghanem RC, Azar DT. Femtosecond-laser arcuate wedge-shaped resection to correct high residual astigmatism after penetrating keratoplasty. *J Cataract Refract Surg.* 2006;32:1415–1419.
31. Ilari L, Daya SM. Corneal wedge resection to treat progressive keratoconus in the host cornea after penetrating keratoplasty. *J Cataract Refract Surg.* 2003;29:395–401.
32. Buzard KA. Circumferential block resection to reduce myopia. *Refract Corneal Surg.* 1993;9:283–292.
33. Krachmer JH, Robert EF. Surgical correction of high postkeratoplasty astigmatism relaxing incisions vs wedge resection. *Arch Ophthalmol.* 1956;98:1400–1402.